

# Teeth clipped-out in Javanese Slow Loris (*Nycticebus javanicus*) and Its Preservation Through Root Canal Treatment

**Bagus Brahmanto Aji Guno, DVM., M.Sc.<sup>1</sup>, Randy Kusuma, DVM<sup>2</sup>,  
Muhammad Ihsannul Taqwim, Amd.Vet<sup>1</sup>**

<sup>1</sup>DjiO Pet Care + Vets Clinic, Yogyakarta, Indonesia. <sup>2</sup>Gembira Loka Zoo, Yogyakarta, Indonesia.

Corresponding author: djiopetscare@gmail.com; medic@gembiralokazoo.com

## Abstract

*Nycticebus javanicus* or often called the Javan slow loris is one of Indonesia's endemic primates whose status is now in the critically endangered category because their numbers are decreasing. The illegal trade often causes serious problems for the health and survival of slow lorises in their natural habitat. There is a wrong perception that the teeth of slow lorises are poisonous, which makes illegal traders cut or even pull out the teeth of slow lorises indiscriminately. Slow lorises (*Nycticebus spp.*) are obligate exudativators that gouge at tree bark with their teeth. In addition to functioning for the process of eating, slow loris teeth also function for defense mechanism and allogrooming. Amputation of dental crowns or crown fractures in slow lorises can be a serious problem. Slow lorises do not survive either slowly in rehabilitation centers due to changes in diet or even faster in their natural habitat when being released. Root canal treatment as an effort that can be taken to maintain the damaged or broken teeth, so as to prevent tooth from infection and maintain the function of slow loris teeth to survive in its natural habitat. The method of root canal treatment involve three fundamental component: root canal shaping, disinfection and obturation. Teeth restoration to be performed after obturation, using composite. Teeth that have been successfully treated provide an opportunity for slow lorises to express their natural behavior as well as in surviving in their natural habitat.

*Keywords* : Slow loris, illegal trade, tooth fracture, root canal treatment, natural behaviour

## Introduction

All Asian slow lorises are threatened with a crushing defeat against their habitat, or even greater immediate threat due to a high demand in Asia for pets and traditional medicine trade (Schulze and Groves 2004; Streicher 2004). Easy to catch due to their slow locomotion and their slow reproduction factor, numbers of lorises in animal markets far outstretch to their population numbers in the wild (Shepherd *et al.* 2004). Indeed, this threat raised international concern, which is transferring of all members of the genus *Nycticebus* to CITES Appendix I in 2007 (Nekaris and Nijman 2007). Five species of slow loris are now recognized: *N. coucang* (greater), *N. pygmaeus* (pygmy), *N. bengalensis* (Bengal), *N. menagensis* (Bornean), and *N. javanicus* (Javan) (Roos 2003; Chen *et al.* 2007). All slow lorises suffer from trade throughout their range, but when combined with tremendous habitat loss, no other species has been harder hit than the Javan slow loris (Nekaris *et al.*, 2008).

The existence of the Javan slow loris is increasingly threatened due to the loss of much of its original habitat and the high level of trade in the animal market (Suprijatna & Wahyono 2000: 22; Nekaris & Munds 2009: 2; IUCN 2013: 1). Slow lorises in Indonesia have been protected since 1973 by Indonesia Law No. 5 of 1990 concerning Conservation of Biological Resources and Their Ecosystems, and Government Regulation (PP) No. 7 of 1999 concerning Preservation of Plant and Animal Species. In addition, the Javan slow loris is also included in Appendix I, which is a species that is prohibited from being traded for any reason, except for conservation purposes and must be signed with an agreement between countries (CITES 2007: 1-2).

The high number cases of cutting teeth in slow lorises which are traded triggers the emergence of cases of tooth infection due to the practice of cutting teeth in an unethical manner using clipped nails or pliers. The practice of cutting teeth is intended so that potential maintainers do not get bitten. There is a misconception that slow loris teeth are poisonous when biting,

making these illegal cutting of teeth is a mandatory when trading slow lorises.

The teeth of slow lorises are actually not poisonous. The sweat glands that secrete noxious oil are underneath their armpits. When slow lorises are scared, they will raise their hands and lick their armpits so that their oral cavity and also teeth are full of poison which can cause vomiting, fever and swelling when bitten. Those noxious oil will reacted by the saliva and form a toxic compound (Nekaris et al., 2013).

The practice of cutting teeth in slow lorises will reduce their ability to be released back into their natural habitat, related to their ability to access food in nature. Teeth are an important part of primates. In addition to helping the digestive process and as a means of self- defense from threats, teeth are also an indicator of age and health status. The dental formula for slow lorises is  $2\ 1\ 3\ 3 / 2\ 1\ 3\ 3$ , namely two incisors, one canine, three front molars and three rear molars in each jaw starting from the midline (Coote, 2005), with the frontmost pre-molar teeth have a canine-like structure. Each tooth shape has its own function.

Tooth fracture are classified based on the location (crown, crown-root or root) and whether the pulp is exposed (uncomplicated or complicated). A complicated crown fracture is a fracture of the crown that exposes the pulp. The opened pulp may lead to be pulpitis and pulp necrosis. Pulpitis is causing dystrophic mineralization of the pulp and leading to narrowing or complete disappearance of the pulp cavity. Pulp necrosis is a sequel to untreated irreversible pulpitis, a traumatic injury or events that cause long term interruption of the blood supply to the pulp. A tooth with necrotic pulp is called a non vital pulp (Reiter & Gracis,2018).

Endodontic therapy is the treatment of the dental pulp. Dental pulp consists of blood vessels, nerves, and connective tissue that support odontoblastic cells and provide internal sensory and metabolic function to the interior of the teeth. The pulp is the innermost part of the tooth (Holmstrom, 2011). Endodontic treatment is indicated to preserve a tooth when pulpal necrosis

happened because of apical periodontitis (38.1%), followed by pulpitis (37.7%) (Wigsten *et al.*, 2018). In Veterinary Medicine, most of the causes is a fracture of the crown exposes the pulp chamber or the root canal. A carious erosion has perforated either the pulp chamber or the root canal. A pulpal injury is present that results in hemorrhage or necrosis either in an open or a closed pulp canal (Holmstorm, 2011).

Root Canal treatment is commonly performed in Veterinary Dentistry in a attempt to retain periodontally strategic teeth that are affected by pulpal injury. Well defined general procedural principals have been developing adapting mainly techniques from human endodontic methodology and applied to the specific anatomy of animal teeth (Harvey & Emily, 1995). A rational for root canal treatment is much less invasive than surgical extraction of a large canine or carnassial tooth, and so it is an easier and quicker procedure to perform. Standard root canal therapy is less traumatic for the patient and more aesthetically pleasing to the owner than surgical extraction (Holmstorm, 2011).

The principals of Root canal therapy is a treatment which involves removing infected pulp from the root canal of the tooth, sterilizing the canal, and replacing the removed tissue with dental material (Hiscox, 2022). In this procedure, the pulp canal is approached in a normograde direction (from the crown to the apex). The entire pulp is removed through either the fracture site or one or more drilled access holes. Standard root canal therapy is indicated for adult teeth that are discolored and endodontically dead or that have been contaminated with long-standing infection. In a mature tooth, a long-standing infection is one in which the pulp has been contaminated for more than 48 hours (Holmstorm, 2011).

## Material and Methods

The anesthesia process begins with initiation using Ketamine (Ketamil®) and Acepromazine (Castran®), followed by intubation (endotracheal tube size 2.0) with gas anesthesia using isoflurane. Overall dental evaluation was carried out with a dental probe (IM3Vet®) and dental explorer (IM3Vet®) and the condition of each tooth was recorded on the dental chart for primates. Evaluation of the root canal should be carried out using a DR x- ray (Toshiba®) for the entire head, followed by measuring the length of the root canal to be repaired. Measuring the length of the root canal is essential because it determines the length of the dental file like barbed broach (Spiro Colorinox®), k-file (Dentsply®) and h-file (Dentsply®) to be used, as well as the length of the obturation material like gutta perch (Meta Biomed®) to be filled into the root canal.

Based on this treatment goal, endodontic procedures have developed from mechanical to more biological in nature maintaining three fundamental components: root canal shaping, disinfection and obturation. Failure of endodontic therapy may occur if any of these components are performed poorly (Ruddle, 2002).

Root canal shaping is the first step devoted to preparing endodontic cavity allowing endodontic materials and instruments to move without impediment within the coronal part of the root canal hence the term *access for success*. Inadequately shaped canals can not be cleaned efficiently, even if pulp tissue has been removed from root canal. After opening the root canal to a greater extent with an open-access bur (Dentsply®) and high speed handpiece (DynaLED®), the next step is devoted to enlargement of the coronal two third of the root canal. This method removes restrictive dentin, thus reducing pressure form most of the coronal cutting flutes of any endodontic file; creates a reservoir for irrigants; increasing their working time for penetration and circulation; and reduces the amount of debris inadvertently pushed down into the periapical

area (Ruddle, 2002). This root canal enlargement can use rotary files hand-use (Dentsply Protaper®).

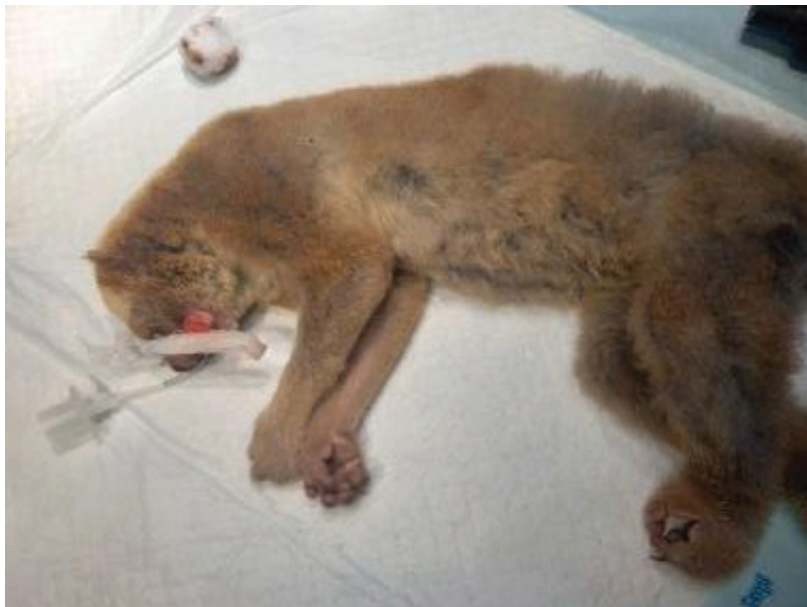The second step is disinfection of root canal. Effective irrigant delivery and agitation are prerequisites to promote root canal disinfection and debris removal to improve successful endodontic treatment. The main aim is to disinfect the entire root canal system, which requires elimination of microorganisms and microbial components, also prevention of its re-infection during and after treatment. This step is pursued by chemo-mechanical debridement, where the mechanical systems are associated with the irrigating solutions (Plotino *et al.*, 2016). One of the standard endodontic irrigation protocol is using Sodium Hypochloride (NaOCl) (Onemed®) and Chlorhexidine (CLS® by IM3Vet). Final step of disinfection is drying the root canal using paper point

The next stage is obturation. The obturation stage is carried out to fill the root canal in an attempt to provide a hermetic seal from the coronal orifice of the canal to the apical foramen at the cementodentinal junction. However, it is important to recognise that the responsibility does not end here; the coronal seal forms an integral part of endodontic treatment and therefore plays a vital role in the treatment's success (Ray & Trope, 2005). The material that we used for obturation step is Gutta Percha (Meta Biomed®), EDTA gel (Prosimi®) as chelating agent, and Glass Ionomer Cement (GC Fuji®) as sealer.

After the root canal treatment is complete, the next step is tooth restoration. Beginning with the application of Blue Etch Acid on the surface of the enamel and dentin for 15 seconds, then wash and dry it with a micro-brusher. The second step, apply restoration bond and irradiate it with Lightcure for 10 seconds. Ended by covering the surface of the crown fracture with flowable composite, and irradiated with lightcure for 20 seconds. Then use composite polisher with low speed handpiece for leveling the composite patch.

## Result and Discussion

There are 2 confiscated Javan slow lorises from local residents which will be prepared for the rehabilitation process, both of them had severe dental conditions in which several experienced crown fracture, both complicated and uncomplicated due to careless clipped out of teeth procedure by illegal trader. All dental treatments are carried out under general anesthesia, including dental examination with a dental probe and explorer, as well as the x- rays. Anesthesia of the slow loris begins with an injection of Ketamine and Acepromazine, followed by the installation of gas anesthesia using Isoflurane through a Size 2.0 Endotracheal tube.



Picture 1. The slow loris under general anesthesia and intubation using endotracheal tube 2.0

After a complete dental examination was carried out, it was found that many teeth were in a state of severe condition. Its more due to fractures of many dental crowns. The complete dental examination data for the two slow lorises can be seen in the table 1.

Table 1. Complete dental examination data of two Javan Slow Loris

Loris	Maxilla			
	Incisivus	Caninus	Premolar	Molar
Normal Reference	4	2	6	6
Loris A	2 MT 2 RF	2 CCF	2 UCF 4 N	6 N
Loris B	2 MT 2 N	2 CCF	2 UCF 4 N	6 N

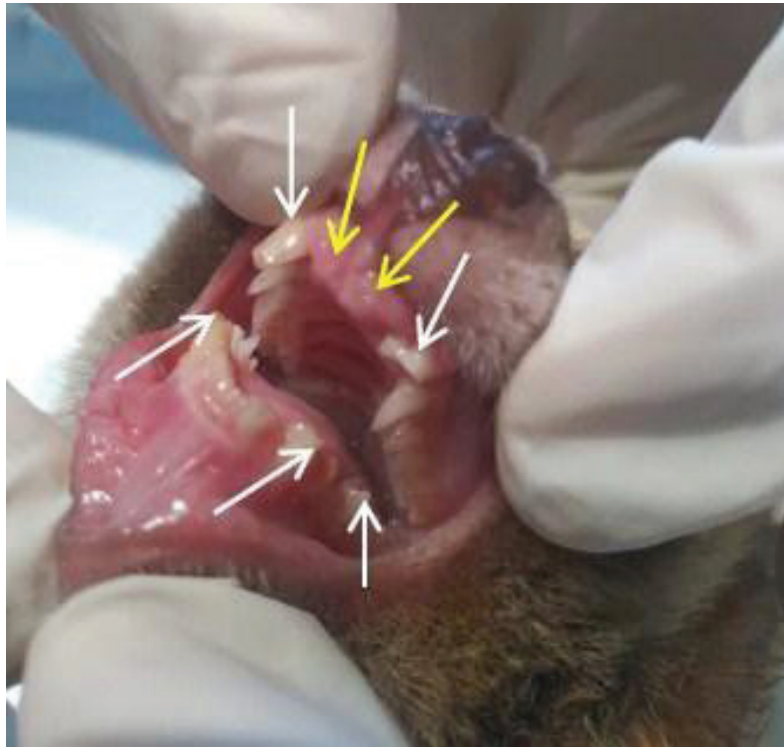Loris	Mandibula			
	Incisivus	Caninus	Premolar	Molar
Normal Reference	4	2	6	6
Loris A	4 N	2 CCF	1 CCF 1 UCF 4 N	6 N
Loris B	4 N	1 CCF 1 N	2 UCF 4 N	6 N

(N = normal; MT = Missing Teeth; CCF = Complicated Crown Fracture; UCF =Uncomplicated Crown Fracture; RF = Root Fracture).

Based on the data above, it shows that both of Javanese slow lorises experienced complicated crown fractures for all the canines, whereas Slow loris A has an incomplete number of teeth where there are 2 missing incisors so that the total number of teeth is only 34. Slow loris A also has 2 root fracture of incisors that should be solved by extraction. Slow loris B has a complete number of teeth (36 teeth).

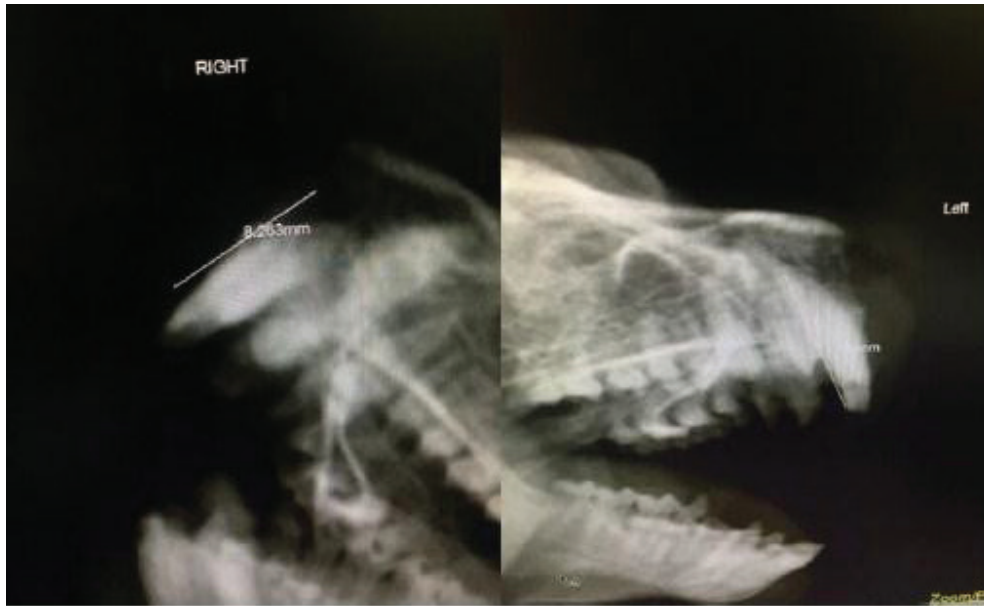




Picture 2. Dental Examination and Dental Charting showed that all four canines and one mandibular premolar (canini like) had complicated crown fractures (exposed tooth pulp) marked with white arrows and two incisors had complicated root fractures (broken and left tooth roots) marked with yellow arrows.

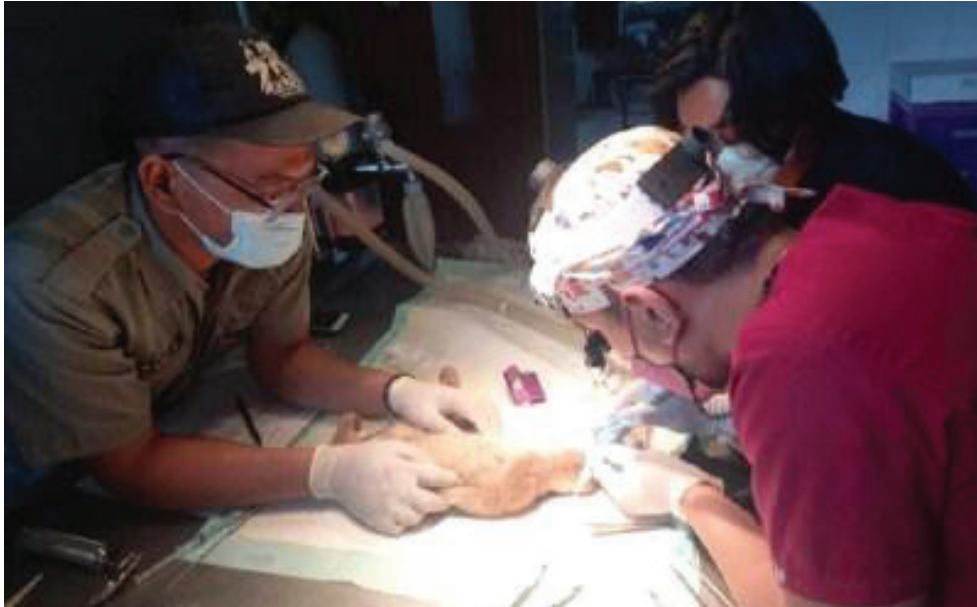An endodontic procedures, namely root canal treatment, are performed for all the canines of both slow lorises, while exodontic procedures (tooth extraction) are performed for 2 incisors with left roots. All canines are found no peripockets, examined using a dental probe and confirmed with DR x-ray, so it is good to do root canal treatment on all four canines.

X-Ray evaluation to determine the type of crown or root fracture and measure the length of the root canal, while also looking at the structure of the periodontal tissue consisting of the periodontal ligament, gingival sulcus and periapical area, shows good condition so that Root Canal Treatment (PSA) is prioritized over tooth extraction . Ideally it should be done using a dental x-ray.



Picture 3. DR x-ray evaluation shows that all four canines have complicated crown fracture. Measurement the length of root canal shows different length for each canines

After the size of the root canal is obtained, root canal treatment begins with 3 main steps, namely reshaping the root canal, disinfection and obturation. Root canal shaping is the first step devoted to preparing endodontic cavity. Its very important because its allowing endodontic materials and instruments to move without impediment within the coronal coronal part of the root canal hence the term *access for success*. Inadequately shaped canals can not be cleaned efficiently, even if pulp tissue has been removed from root canal. This first step is devoted to enlargement of the coronal two third of the root canal. This method removes restrictive dentin, thus reducing pressure form most of the coronal cutting flutes of any endodontic file; creates a reservoir for irrigants; increasing their working time for penetration and circulation; and reduces the amount of debris inadvertently pushed down into the periapical area (Ruddle, 2002). This step begins by opening the orifice with an open- access bur, widening the orifice with a protaper file and continuing with root canal preparation with k-files and h-files whose length must be the same as the length of the root canal (measurement by DR x-ray).



Picture 4. The three main steps of root canal treatment were performed for both slow lorises. The second step is disinfection of root canal. The principals of this step is effective

irrigant delivery and agitation are prerequisites to promote root canal disinfection and debris removal to improve successful endodontic treatment. The main aim is to disinfect the entire root canal system, which requires elimination of microorganisms and microbial components , also prevention of its re-infection during and after treatment. This step is pursued by chemo-mechanical debridement, where the mechanical systems are associated with the irrigating solutions (Plotino *et al.*, 2016). One of the standard endodontic irrigation protocol is using Sodium Hypochloride (NaOCl) and Chlorhexidine (CHX).

Sodium hypochlorite (NaOCl) is the main endodontic irrigant used, due to its antibacterial properties and its ability to dissolve organic tissues (Zehnder, 2011). Its effectiveness has been shown to depend on its concentration, temperature, pH solution and storage conditions. Heated solutions (45-60 °C) and higher concentrations (5-6%) have greater tissue-dissolving properties (Beus *et al.*, 2012). However, the greater the concentration the more severe is the potential reaction that may happen if some of the irrigant is inadvertently forced into the

periapical tissues. To reduce this risk, use of specially designed endodontic needles and a technique of injection without pressure are recommended (Kishen, 2010). The main disadvantage of NaOCl is its inability to remove the inorganic portion of smear layer.

CHX should not be used together with or immediately after sodium hypochlorite. CHX is hindered by its interaction with NaOCl, which tends to create products that may discolor the tooth and precipitates that may be potentially mutagenic (Basrani *et al.*, 2007). Both of slow loris only use NaOCl as disinfection agent for the root canal, but the CHX only use for clean up the teeth surface (not enter into the root canal). This second step ends with drying the root canal with a paper point. Drying of the root canal is necessary so that the obturation material can fix well fill into the root canal. the use of standardized absorbent paper points are extensively used in endodontic therapy, not only to dry root canals after irrigation, but also to carry antiseptic or disinfecting dressings, and to transfer bacteriological samples from the root canal to the culture medium (Sune *et al.*, 1998).

The next step is obturation. The obturation stage is carried out to fill the root canal in an attempt to provide a hermetic seal from the coronal orifice of the canal to the apical foramen at the cementodentinal junction. However, it is important to recognise that the responsibility does not end here; the coronal seal forms an integral part of endodontic treatment and therefore plays a vital role in the treatment's success (Ray & Trope, 2005).

The aim of obturation is to establish a fluidtight barrier with the aim of protecting the periradicular tissues from microorganisms that reside in the oral cavity. While a perfect airtight or hermetic seal is unachievable in reality, every effort should be made to reach this target.

The establishment of a well obturated system would serve three main functions: 1.) Prevent coronal leakage of microorganisms or potential nutrients to support their growth into the dead space of the root canal system 2.) Prevent periapical or periodontal fluids percolating into the

root canals and feeding microorganisms 3.) Entomb any residual microorganisms that have survived the debridement and disinfection stages of treatment, in order to prevent their proliferation and pathogenicity (Sundqvist & Figdor, 1998).

The material that we used for obturation step is Gutta Percha and Glass Ionomer Cement as sealer. Gutta percha (GP) is the most commonly used root filling material, it is a naturally occurring rubber with the chemical name trans-1,4-polyisoprene. GP in a traditional form contains zinc oxide (65%), gutta percha (20%), radio opacifier (metal sulphate) (10%) and plasticiser (5%) (Friedman *et al.*, 1997). For the sealer, although they adhere to dentine, glass ionomer-based sealers have been shown to be more soluble and exhibit less antimicrobial activity than both zinc oxide eugenol and calcium hydroxide-based sealers. They can also be more difficult to remove for any correction or retreatment (Weiger *et al.*, 1995).

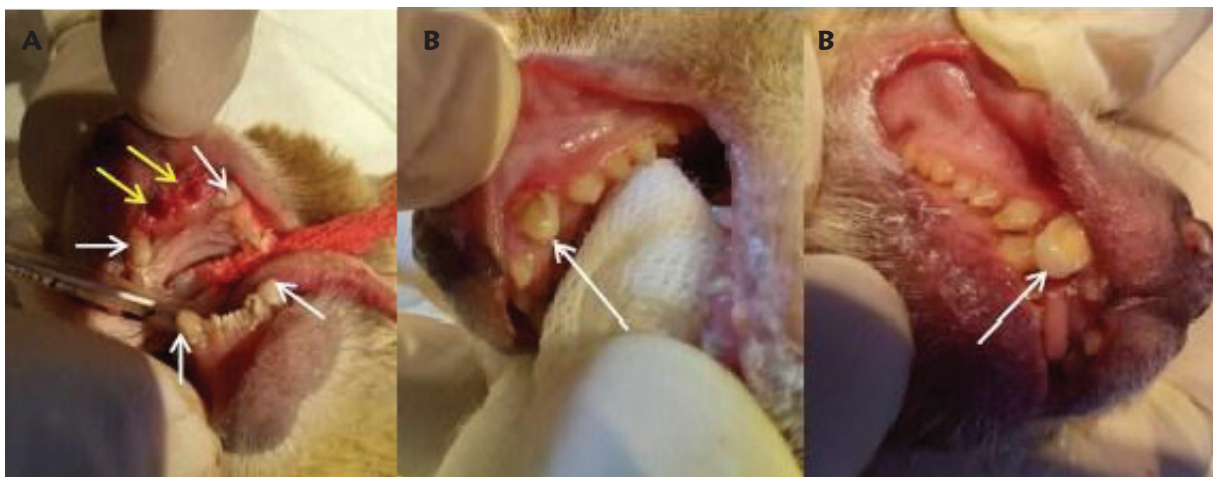
After the three steps of root canal treatment are completed, the next step is tooth restoration. The stages of tooth restoration include applying Blue etch acid to the enamel and dentin; applying restorative bond and applying the composite. Blue Etch Acid allows bonding of the composite to the enamel surface. Etch is an acidic chemical that functions to remove mineralized surface of the tooth and form microporous which make up the surface of the enamel becomes rough, so that the composite resin can penetrate inside tooth surface and forms a resin tag. The depth of microporous depends on the length of the etching process and sufficient rinsing time to produce an adequate etching pattern (Anusavice, 2003).

After rinse the blue etch acid and dry it well using microbrusher, the next step is application of restorative bond on the teeth surface and irradiated with Lightcure for 10 seconds. Dentine adhesive/bonding materials is applied to the dentin surface during 15-20 seconds, using a brush or applicator tip. Movement agitation or light rubbing can used during application to facilitate infiltration of material onto the dentin surface which has been etched (Fibryanto,



2020). The usage of lightcure after the application of restorative bond will strengthen the dentine bond to the composite material (Catelan *et al.*, 2014).

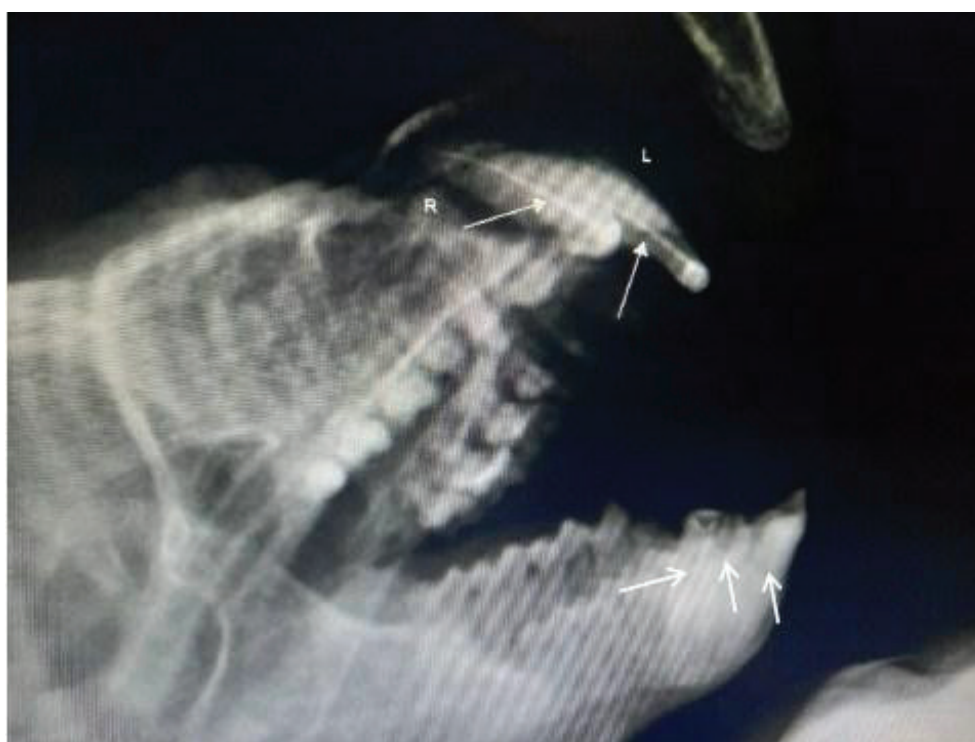The last step of restoration is application of flowable composite evenly over the dentine, then Lightcure for 20 seconds. These composites, which are mostly hybrids, are recommended for specific clinical indications (occlusal microcavities, slot cavities, cervical cavities or dentine substitutes, for example). Due to their fluidity, they show easy spreading, associated with good adaptation to cavity walls. These composites are useful for thin films. They are preferred in the step consisting in covering the bottom of the cavity before adding a more viscous composite (Chapute and Faure, 2021). The result of root canal treatment and restoration in both of slow lorises may be seen in picture 5.



Picture 5. A. the remaining root has been removed (yellow arrows), whereas four canines and one premolar such as a canini or canini-like (white arrows) after root canal treatment and restoration for slow loris A., B. Two canines of maxilla after root canal treatment and restoration in slow loris B.

It is necessary to confirm the results of root canal treatment and restoration using DR x-rays. Good results will indicate that the obturation material completely filled the root canal and the composite successfully closed the orifice. From a radiographic point of view, several criteria

for success of endodontic therapy are generally accepted. These include healing (or at least regression) of recent osseous rarefaction, normal (or only slightly thickened) periodontal ligament space, normal lamina dura, missing evidence of resorption, and a dense and homogeneous three-dimensional obturation of the root canal system, including a sufficient coronal restoration (Kielbassa *et al.*, 2017). The evaluation post root canal treatment may be seen on picture 6.



Picture 6. The root canal treatment area is indicated by the presence of obturation material in the root canal with radiopaque appearance (white arrows).

## Conclusions

The procedure of clipping out the teeth indiscriminately by illegal traders is a clear violation of animal welfare, apart from endangering their health and survival ability as well. The wrong clipping-out teeth procedure makes the slow lorises feel discomfort, pain, leading to infection/ diseases happen, and could not express the normal behaviour. When the teeth is clipped-out,

the slow lorises lose its ability to survive from predators, making it prone to stress and fear. Also prohibit them to express their normal behaviour, especially for doing allogrooming which is depend on the function of insicivus, canines, and canini-like premolar mandibular teeth to groom their fur. The clipped-out teeth procedure also prohibit them to get the access to their normal diet in wildlife habitat. Root canal treatment is an endodontic treatment for preservation the normal function of their teeth.

### **Acknowledgement**

Thank you for all the medic team of Gembira Loka Zoo and its management who are really concern about the slow loris health and their abilty to survive in normal habitat. A good collaboration for doing veterinary dentistry gives a preservation of the teeth function.



## References

- Anusavice, K.J., 2003. *Phillip's Science of Dental Materials*. 11th edition. Florida : Saunders Elsevier. Pp. 58-59.
- Basrani BR, Manek S, Sodhi RN, Fillery E, Manzur A. 2007. Interaction between sodium hypochlorite and chlorhexidine gluconate. *J Endod.*:33:966-999.
- Beus C, Safavi K, Stratton J, Kaufman B. 2012. Comparison of the effect of two endodontic irrigation protocols on the elimination of bacteria from root canal system: a prospective, randomized clinical trial. *J Endod* .(38) :1479-1483.
- Catelan, A., Soares, G.P., Russo, A.K., Lima, D.A.N., Marchi, G.M. and Agular, H.B. 2014. Impact of light-curing time and aging on dentin bond strength of methacrylate- and siloranebased restorative systems. *Braz J Oral Sci*. Vol.13 (3) : 213 – 218.
- Chapute, F. and Faure, A.C. 2021. *Dental Composite*. Techniques de l'Ingénieur. Technologies Biomédicales. hal-03453701f
- Chen, J. H., D. Pan, C. P. Groves, Y. X. Wang, E. Narushima, H. Fitch-Snyder, P. Crow, V. N. Thanh, O. Ryder, H. W. Zhang, Y. X. Fu and Y. P. Zhang. 2006. Molecular phylogeny of *Nycticebus* inferred from mitochondrial genes. *International Journal of Primatology* 27: 1187– 1200.
- CITES. 2007. *Consideration of proposals for amendment of appendices I and II*. The Hague: Pp. 27.
- Coote, Sania Wolfe. 2005. *The Laboratory Primate*. Elsevier, Bengalore – India Pp. 34-35.
- Fibriyanto, Eko. 2020. Bahan Adhesi dan Resin Komposite. *Jurnal Konservasi Gigi Terpadu (JKTG)*. Vol. 2 (1) : 8 -13.
- Friedman C E, Sandrik J L, Heuer M A, Rapp G W. 1997. Composition and physical properties of guttapercha endodontic filling materials. *J. Endod.*; 8: 304–308.
- Harvey, C and Emily, P. 1995. *Small Animal Dentistry*. Mosby Year-Book. St. Louis. Pp. 213- 265.
- Hiscox, Lorraine. 2022. Does My Dog Needs a Root Canal. accessed on November 18 2022. <https://vcahospitals.com/know-your-pet/does-my-dog-need-a-root-canal>
- Holmstrom, Steven E. 2011. *Veterinary Endodontics*. <https://www.vin.com/apputil/content/defaultadv1.aspx?id=5124267&pid=11343>
- IUCN (International Union for the Conservation of Nature and Natural Resources). 2013. *IUCN Red List of Threatened Species*. Version 2014.3. pg. 4. Accessed in November 18 2022. <http://www.iucnredlist.org/details/21494/0> [accessed in 18th November 2022].

- Kielbassa, A.M., Frank, W., and Madaus, T. 2017. Radiologic assessment of quality of root canal fillings and periapical status in an Austrian subpopulation – An observational study. *Journal PONE*: 1 -19.
- Kishen A. 2010. Advanced therapeutic options for endodontic biofilms. *Endod Topics*;22: 99-123.
- Nekaris, K. A. I. & R. Munds. 2009. *Using facial markings to unmask diversity: the slow lorises (Primates: Lorisidae: Nycticebus spp) of Indonesia*. Oxford Brooks University, Oxford: Pp.28
- Nekaris, K. A. I. and V. Nijman. 2007. CITES proposal highlights rarity of Asian nocturnal primates (Lorisidae: Nycticebus). *Folia Primatologica* 78: 211–214.
- Nekaris, K. A. I., Sanchez, K. L., Thorn, J. C., Winarti, I., & Nijman, V. 2008. *International Animal Rescue*. Accessed in November 18 2022.
- <http://www.internationalanimalrescue.org/sites/default/files/client/Javan%20Slow%20Loris.pdf>
- Nekaris, K.A.I., Campbell, N., Coggins, T.G., Rode, E.J. and Nijman, V. 2013. Tickled to death: Analysing public perceptions of ‘cute’ videos of threatened species (Slow Lorises - Nycticebus spp.) on Web 2.0 Sites. *PloS one* 8:e69215
- Plotino, G., Cortese, T., Grande, N.M., Leonardi, D.P., Giorgio, G., Testareli, L. and Gambarini, G. 2016. New Technologies to Improve Root Canal Disinfection. *Braz. Dent. J.* 27 (1) : 3-8
- Ray H A, Trope M. 2005. Periapical status of endodontically treated teeth in relation to the technical quality of the root filling and coronal restoration. *Int. Endod J.*; 28: 12–18.
- Reiter, A. M. and Gracis, M. 2018. *BSAVA Manual of Canine and Feline Dentistry and Oral Surgery*. Wiley Publishing, USA Pp.
- Roos, C. 2003. *Molekulare Phylogenie der Halbaffen, Schlankaffen, und Gibbons*. PhD Thesis, Technische Universität München, München.
- Ruddle CJ. Cleaning and shaping the root canal system. In: Cohen S, Burns RC, eds. *Pathways of the pulp*. 8th ed. St Louis: Mosby 2002;231–291.
- Schulze, H. and C. P. Groves. 2004. Asian lorises: Taxonomic problems caused by illegal trade. In: *Conservation of Primates in Vietnam*, T. Nadler, U. Streicher and Ha Thang Long (eds.). Frankfurt Zoological Society, Frankfurt. Pp. 33-36.
- Shepherd, C., Sukumaran, J., Wich, S.A. and Asia, T.S. 2004: Open season: An analysis of the pet trade in Medan, Sumatra 1997-2001. TRAFFIC Southeast Asia.
- Streicher, U. 2004. Aspects of the ecology and conservation of the pygmy loris *Nycticebus*

*pygmaeus* in Vietnam. Dissertation, Ludwig-Maximilians Universität, Germany.

Sundqvist G, and Figdor D. 1998. *Endodontic treatment of apical periodontitis*. In Ørstavik D, Pitt Ford T R (eds) *Essential endodontology. Prevention and treatment of apical periodontitis*. Blackwell Publisher. Oxford.

Sune, J.P., Vicens, L.S., Vilalta, J.S., Sahli, C.C. and Aguade, E.B. 1998. Absorbency Properties of Different Brands of Standardized Endodontic Paper Points. *Journal of Endodontics*. Vol. 24 (12) : 796 – 798.

Supriatna, J., and Hendra, E. 2000. *Panduan Lapangan Primata Indonesia*. Yayasan Obor Indonesia. Jakarta. Pp. 21-26.

Weiger R, Heuchert T, Hahn R, Lost C. 1995. Adhesion of a glass ionomer cement to human radicular dentin. *Endod Dent Traumatol*; 11: 214–221.

Wigsten E., Jonasson P., EndoReCo & T. Kvist. 2018. Indications for root canal treatment in a Swedish county dental service: patient- and tooth-specific characteristics. *International Endodontic Journal*. doi:10.1111/iej.12998

Zehnder M, Paquè F. 2011. Disinfection of the root canal system during root canal re- treatment. *Endod Topics*;19:58-73.

